

How to... prepare a case or a scientific presentation

David García Azorín

Hospital Clínico de Valladolid, Spain

davilink@hotmail.com

A golden compass rose is shown in the lower-left corner, with a large golden arrow pointing towards the upper-right. The arrow is positioned over a large, faint word 'TRUTH' that is written in a serif font. The background is a light, textured surface with some faint, curved lines. In the top-left corner, there is a black circle with a white border containing the text 'Today's overview'.

Today's
overview

A woman with short, curly dark hair is speaking at a podium. She is wearing a dark blue button-down shirt and has a microphone in front of her. She is smiling and pointing her right index finger upwards. The background is a dark red wall with vertical wood paneling. The text 'The beginning' is overlaid in a white, outlined font across the center of the image.

The beginning

You never get a second chance to make a first impression

My name is...
and I come
from...





Your attitude



"I asked him to smile"

How to... prepare a case or a scientific presentation

David García Azorín, MD, PhD, MSci, FEBN, FEHF

Member of the executive board, Spanish Society of Neurology

Secretary, European Union of Medical Specialists

Chairman, Secondary Headache, Special Interest Group, International Headache Society

Responsible for cooking and cleaning in my house

Lord commander of the imperial force

How to... prepare a conference and a scientific presentation

David García Azorín, MD, PhD, MSc, FEBN, FEHP

Member of the executive board, Spanish Society of Neurology

Secretary, European Union of Medical Specialists

Chairman, Secondary Headache, Special Interest Group, International Headache Society

Responsible for cooking and cleaning in my house

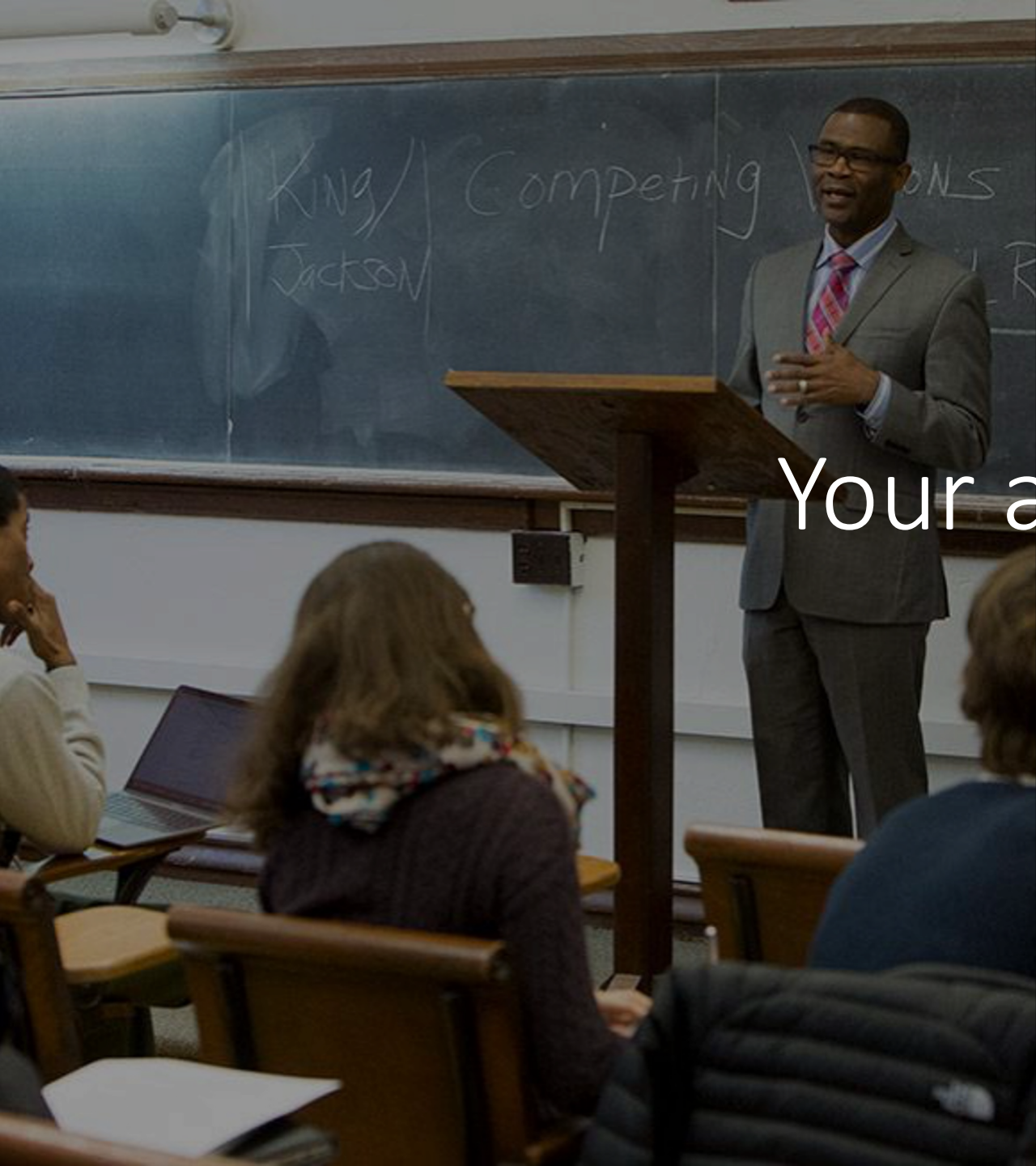
Lord commander of the imperial force



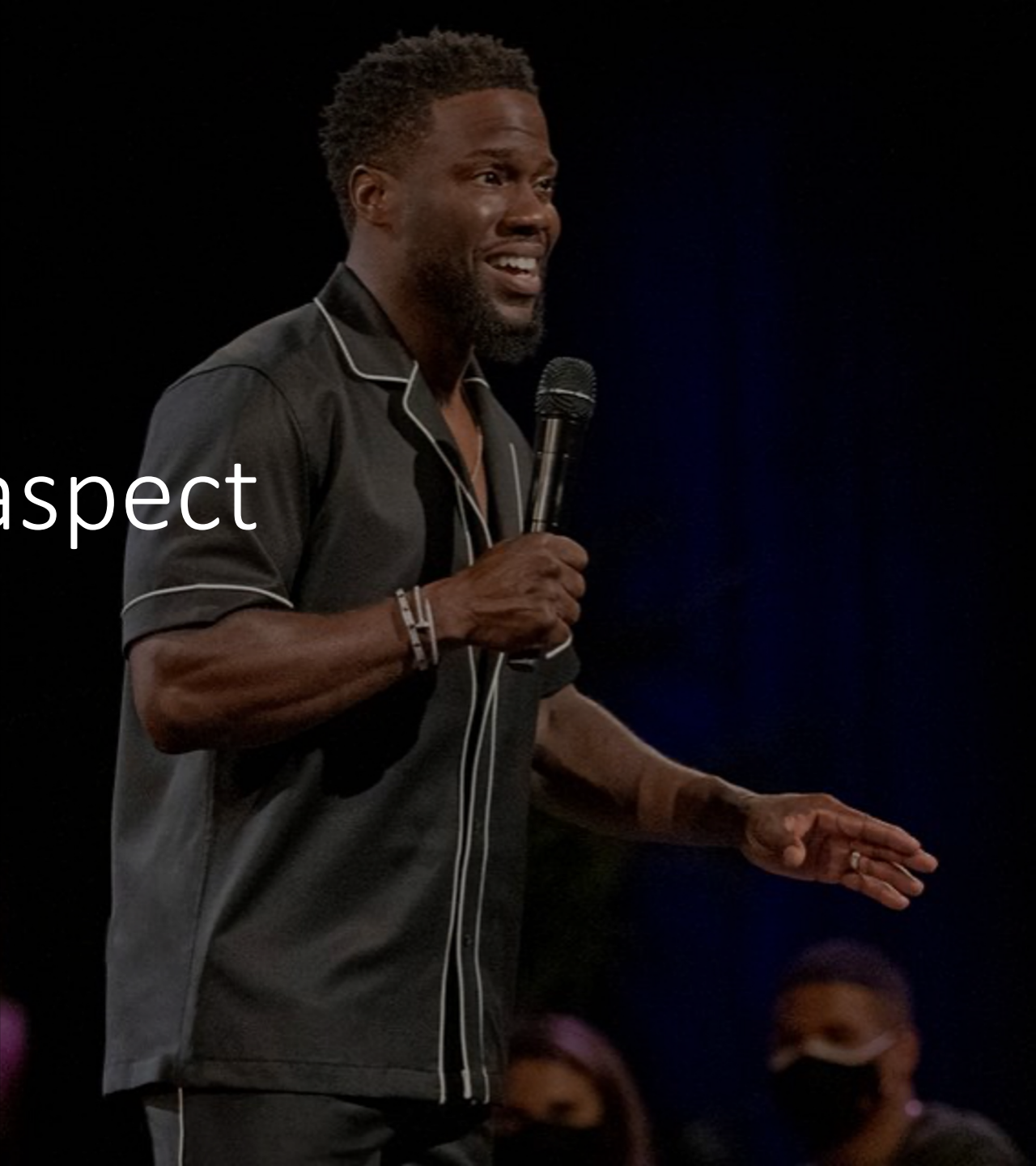Conflicts of interest

Type	Organization/company
Advisory Boards	Allergan, Lundbeck, Teva
Speaker / Speakers Boards	Allergan, Eli Lilly, Novartis, Lundbeck, Chiesi, Teva, Abbvie
Consultant	World Health Organization
Grant support for research or education	International Headache Society, Carlos III institute (Spain)
Editorial Board	Journal of Headache and Pain, Neurological Sciences
Author royalties	





Your aspect



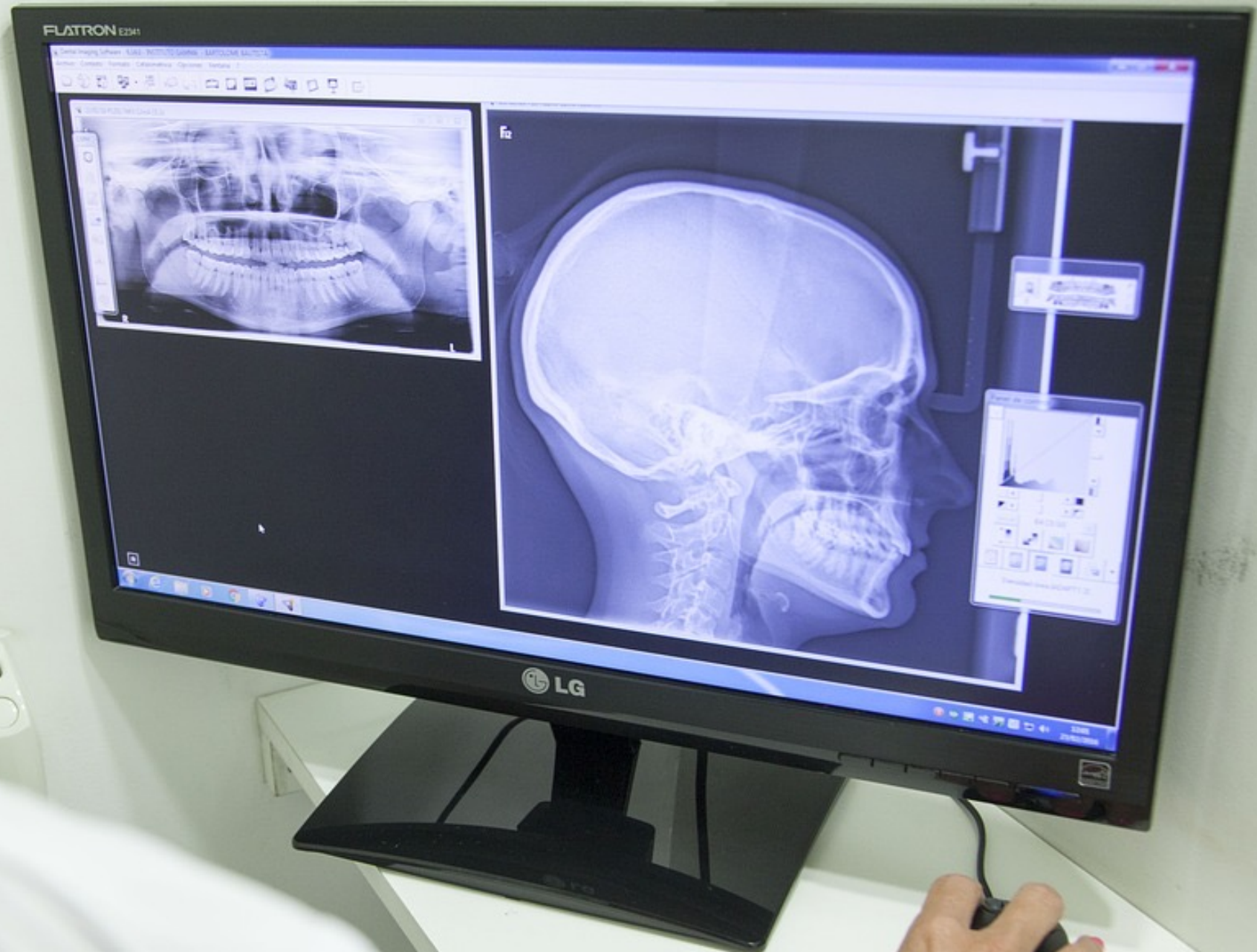

The audience

Visit the
room!



Readable from backwards







The room

11:00 - 11:20 Presidential Symposium



Elvira Ariles
Department of Neurobiology
University of California, San Diego

ean


ean congress

Budapest 2023


Spinal cord injury paralyzes body parts below injury

Brainstem/Brain

Synaptic inputs shape diversification of motor output



Generation of different motor output patterns



11:00 - 11:20 Presidential Symposium



Elvira Ariles
Department of Neurobiology
University of California, San Diego

ean

A close-up photograph of a man with a beard, wearing a blue polo shirt, looking down at his left wrist where he is wearing a watch. The background is a plain, light-colored wall. The word "Time" is overlaid in white text in the center of the image.

Time

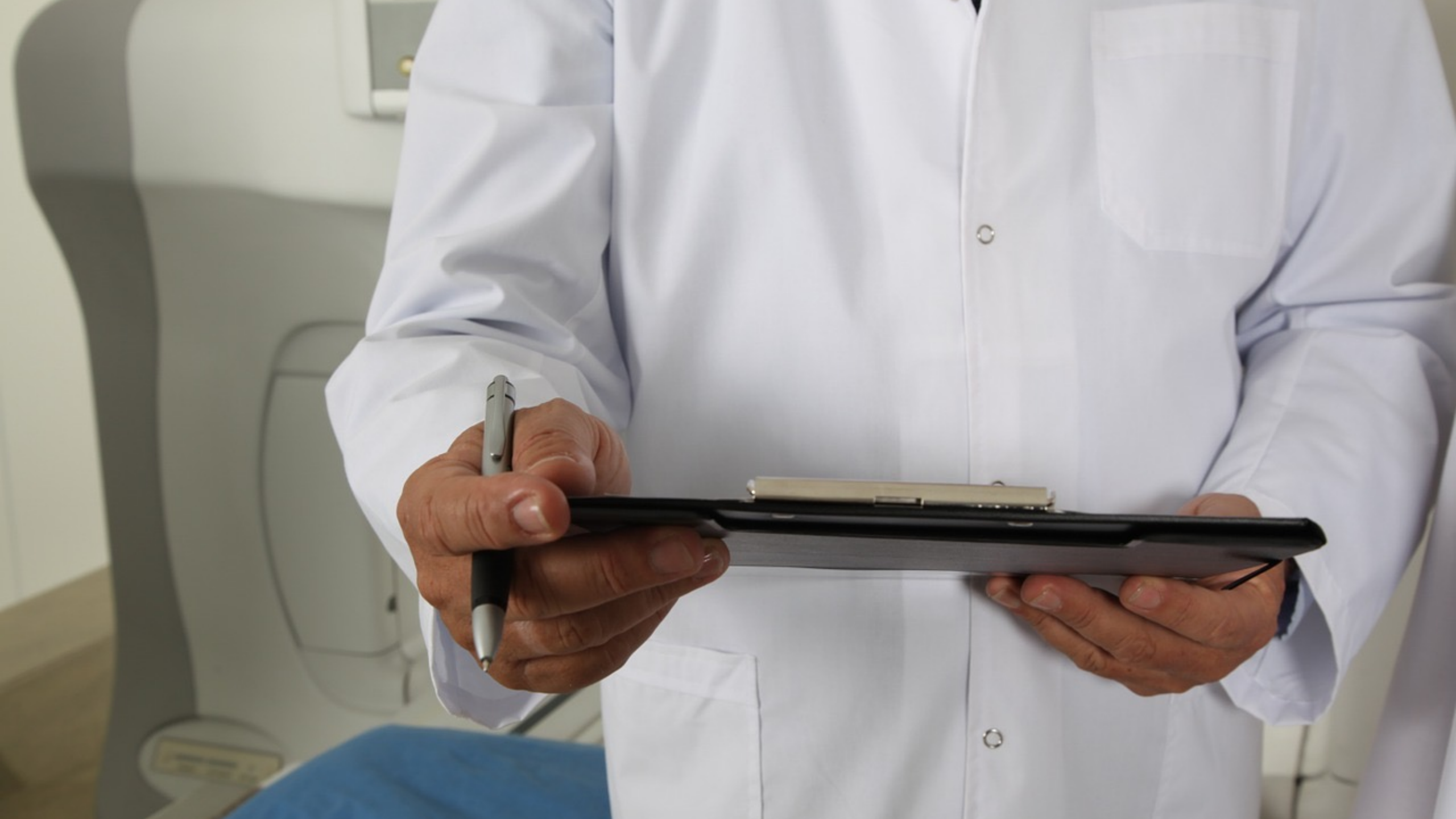






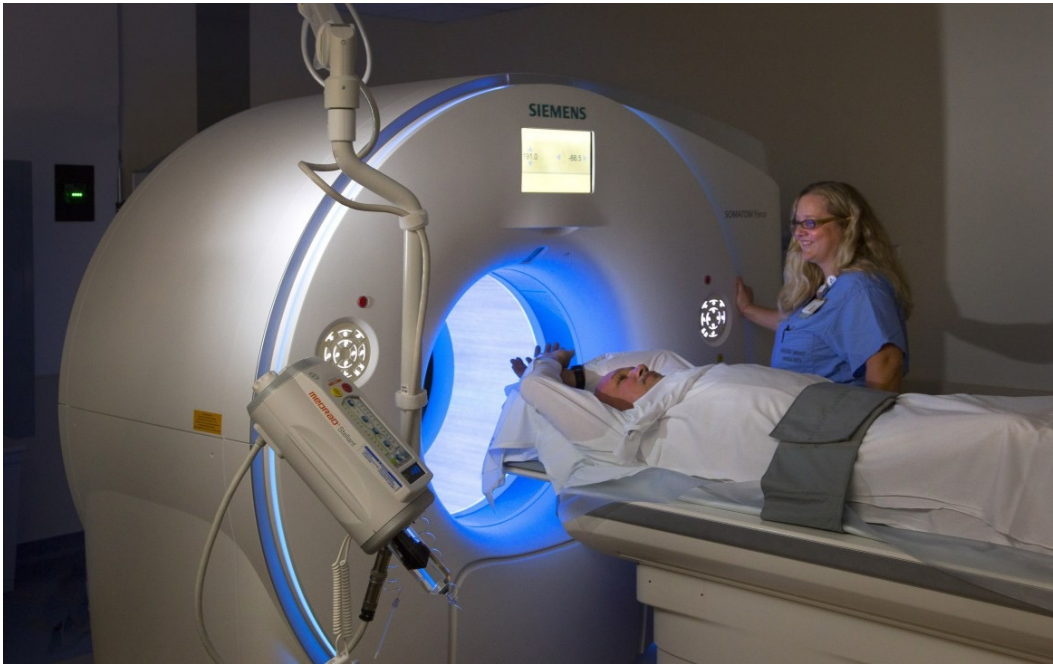


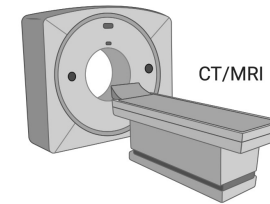


There are 118 causes of high-risk headache

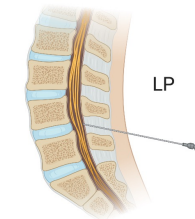
- You must be vigilant and adapt the work-up to the suspected cause



a) Parenchymal evaluation

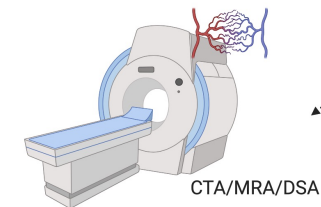


b) CSF composition and pressure



if normal

c) Arterial and venous evaluation



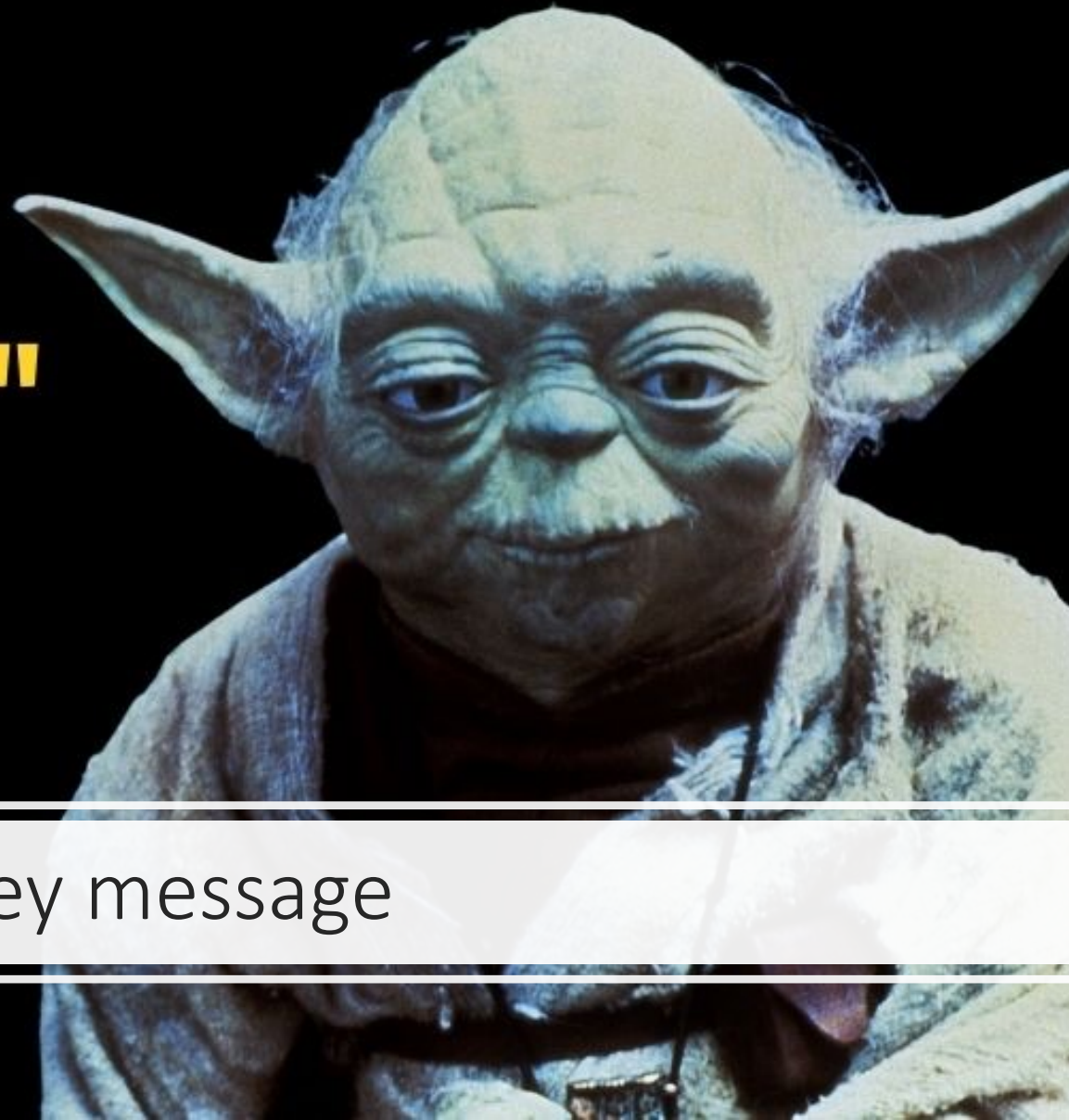
if normal

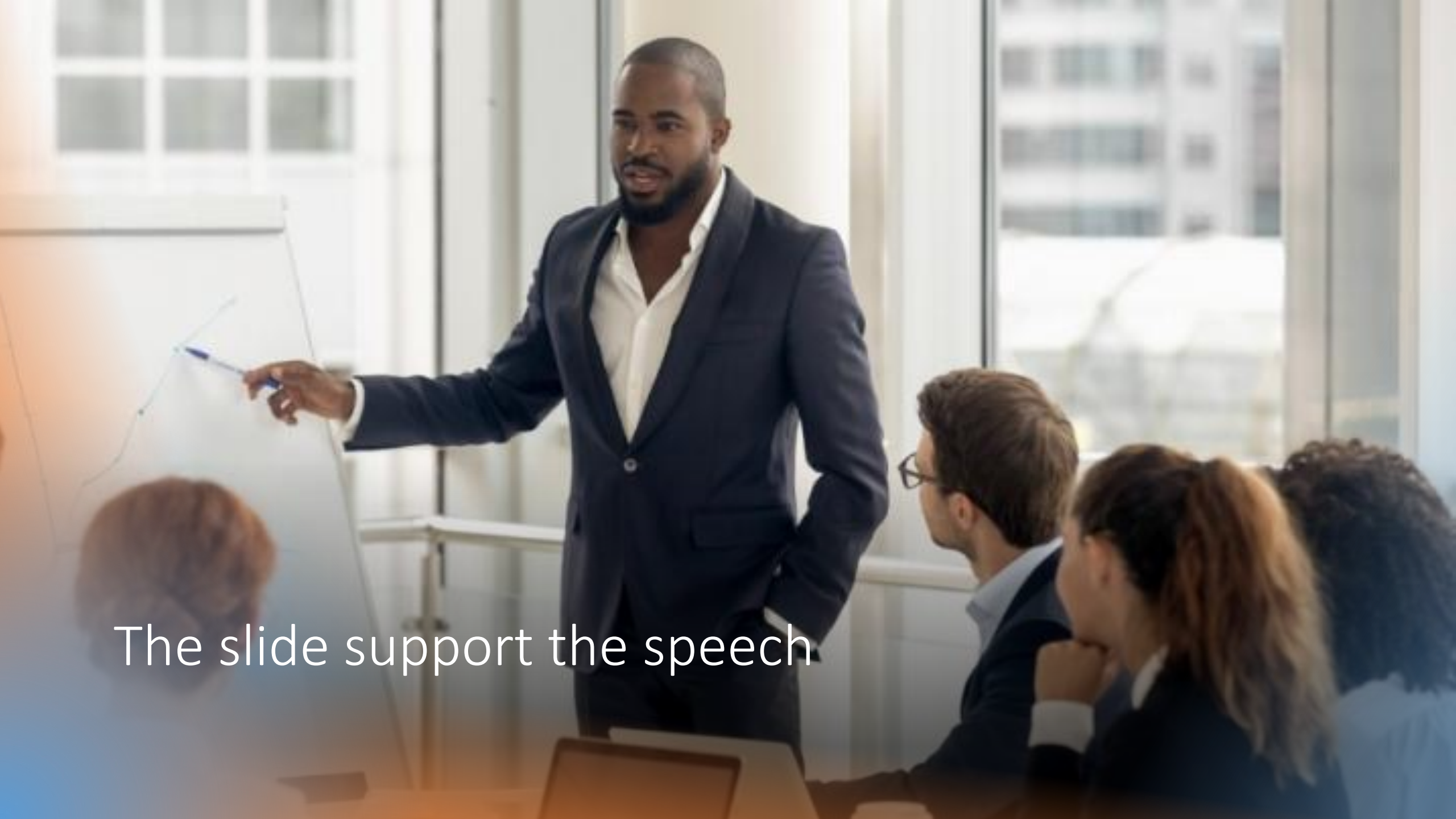**"The greatest
teacher, failure is."**

-Yoda

The title → the key message

Goalcast





The slide support the speech

K-Ras is currently the most effective clinically predictive biomarker

- there are virtually no biomarkers that are useful in predicting response to treatment strategies; the best one at the present time is the presence of K-Ras mutations
- K-Ras is a key cell signaling molecule that acts downstream of receptor tyrosine kinases such as EGFR; activating K-Ras mutations occur in ~ 40% of CRC and K-Ras mutations are associated with poor prognosis and poor survival
- two anti-EGFR monoclonal antibody drugs, cetuximab and panitumumab, are ineffective in patients with activating K-Ras mutations; see McIntire et al pdf

Too many words overwhelms & frustrates people – influence visually

- A foam engine is needed to ensure a rapid response to fires and chemical releases. Risk engineering audits and tactical fire-fighting preplans require that foam suppression capabilities be maintained on site for flammable liquid type fires. The plant is a member of CIMA, which maintains By-laws for conditions of membership. These conditions of membership require that a minimum 1,250 gpm of foam solution is needed for flammable liquid type fires. In addition at least 1,000 gallons of foam storage capabilities are required. If a plant does not maintain an engine the loss of membership in CIMA is a realistic potential. This would result in a much lower response capability in the event of a major fire or spill at the site. In addition to providing fire-fighting and toxic gas suppression capability at the site an aerial would provide rescue capability to 100 feet. This aerial would also satisfy a risk engineering recommendation to provide aerial response to the site as well.

The slides

Key findings of the study

- Headache is uncommon in patients with infective endocarditis
- Its presence seems associated with neurological manifestations
- Patients with headache experience fewer amount of cardiac complications

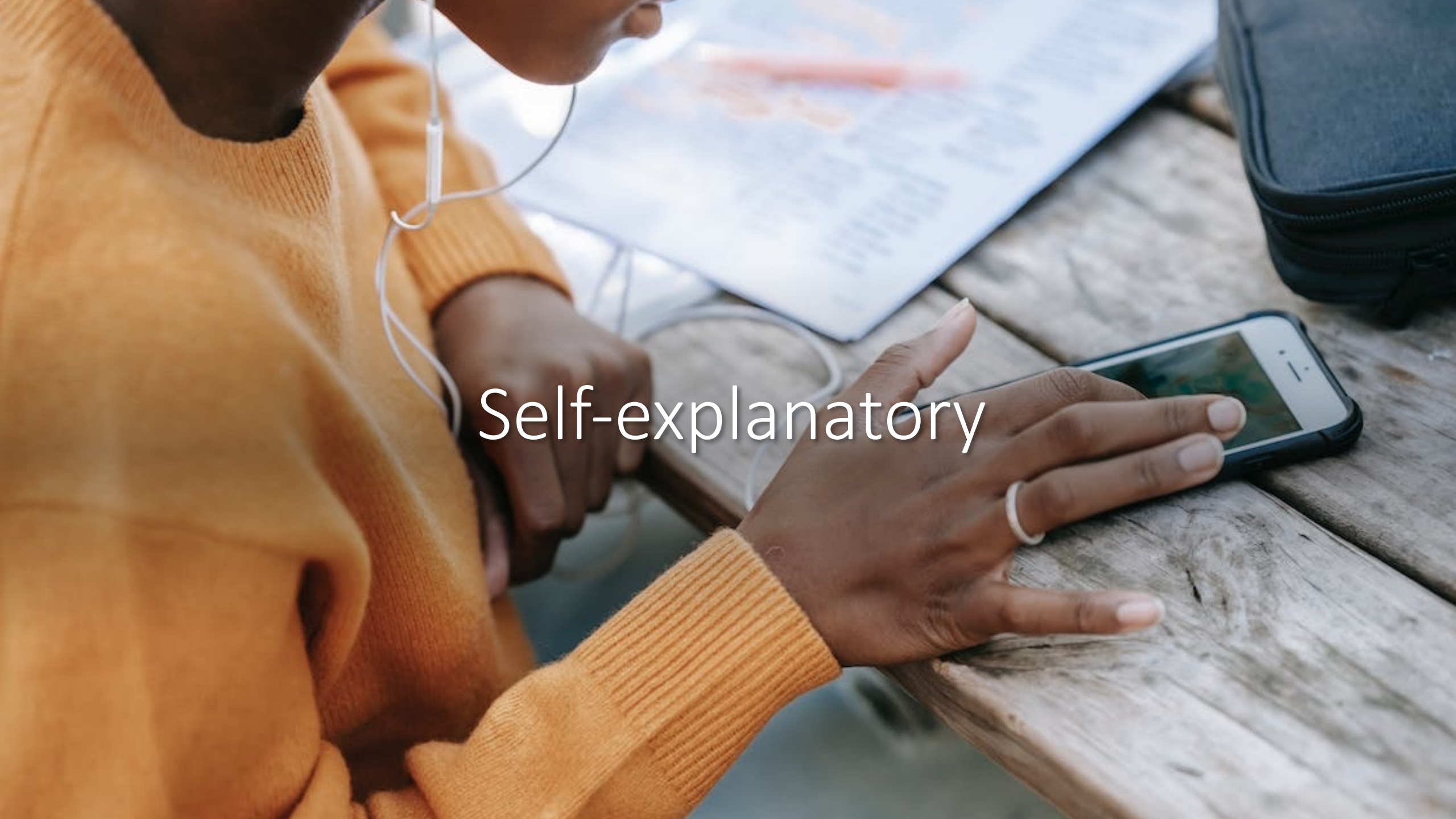



```
...).removeClass("active");  
a.fn.scrollspy=d,this},a(window  
y),+function(a){"use strict";fu  
&e[b]()}})var c=function(b){thi  
ropdown-menu"),d=b.data("target  
st a"),f=a.Event("hide.bs.tab"  
faultPrevented()){var h=a(d);t  
trigger({type:"shown.bs.tab",re  
u > .active").removeClass("act  
ria-expanded",!0),h?(b[0].off  
().find('[data-toggle="tab"]  
de")||!d.find("> .fade").le  
;var d=a.fn.tab;a.fn.tab=b  
"show"));a(document).on("a  
se strict";function b(b)  
=typeof b&&e[b]()}})var  
",a.proxy(this.checkPos  
null,this.pinnedOffset  
tState=function(a,b,c,  
"bottom"==this.affixed  
!=c&&e<=c?"top":null  
.RESET).addClass("af
```



```
...).removeClass("active");  
a.fn.scrollspy=d,this},a(window  
y),+function(a){"use strict";fu  
&e[b]()}})var c=function(b){thi  
ropdown-menu"),d=b.data("target  
st a"),f=a.Event("hide.bs.tab"  
faultPrevented()){var h=a(d);t  
trigger({type:"shown.bs.tab",re  
u > .active").removeClass("act  
ria-expanded",!0),h?(b[0].off  
().find('[data-toggle="tab"]  
de")||!d.find("> .fade").le  
;var d=a.fn.tab;a.fn.tab=b  
"show"));a(document).on("a  
se strict";function b(b)  
=typeof b&&e[b]()}})var  
",a.proxy(this.checkPos  
null,this.pinnedOffset  
tState=function(a,b,c,  
"bottom"==this.affixed  
!=c&&e<=c?"top":null  
.RESET).addClass("af
```

```
...).removeClass("active");  
a.fn.scrollspy=d,this},a(window  
y),+function(a){"use strict";fu  
&e[b]()}})var c=function(b){thi  
ropdown-menu"),d=b.data("target  
st a"),f=a.Event("hide.bs.tab"  
faultPrevented()){var h=a(d);t  
trigger({type:"shown.bs.tab",re  
u > .active").removeClass("act  
ria-expanded",!0),h?(b[0].off  
().find('[data-toggle="tab"]  
de")||!d.find("> .fade").le  
;var d=a.fn.tab;a.fn.tab=b  
"show"));a(document).on("a  
se strict";function b(b)  
=typeof b&&e[b]()}})var  
",a.proxy(this.checkPos  
null,this.pinnedOffset  
tState=function(a,b,c,  
"bottom"==this.affixed  
!=c&&e<=c?"top":null  
.RESET).addClass("af
```

Self-explanatory

Text

...shehasnootherneurologicsymptomsnonumbnessortinglingshedeniesanyvisualchangespastmedicalhistorygallbladderremovalpast surgical history diabetes rheumatoid arthritis hypertension gerd and hypothyroidism medications advairalbuterolallopurinol aspirin clobetasol folic acid fosamax levoxyllisinopril metformin omeprazole plaquenil prednisone testosterone verapamil allergies no known drug allergies social history the patient is married with child she **does not smoke** she does not drink she does not use recreation aldrugs she weighs pounds and is inches tall family history negative for brain aneurysm or other aneurysm it was also negative for heart disease high cholesterol and hypertension and negative for diabetes review of systems the patient is positive for hypertension swelling in the hands or feet leg pain while walking asthma pneumonia shortness of breath gastritis ulcers diabetes thyroid disease urinary tract infections and those symptoms related to the present illness the detail of the review of systems were reviewed with the patient and are included in the neurosurgical health history questionnaire pain the patient has episodic joint pain that is treated with tylenol the patient does not have any nutritional concerns she does not have any safety concerns physical examination...

**F A K E
C T**

Convince

Select the positive/key findings



Case #5: Saturday 28th October, 2023

37 y.o. woman

No relevant prior history. Treatment with oral contraceptives

New onset headache, with progressive worsening, and resistant to acute treatments

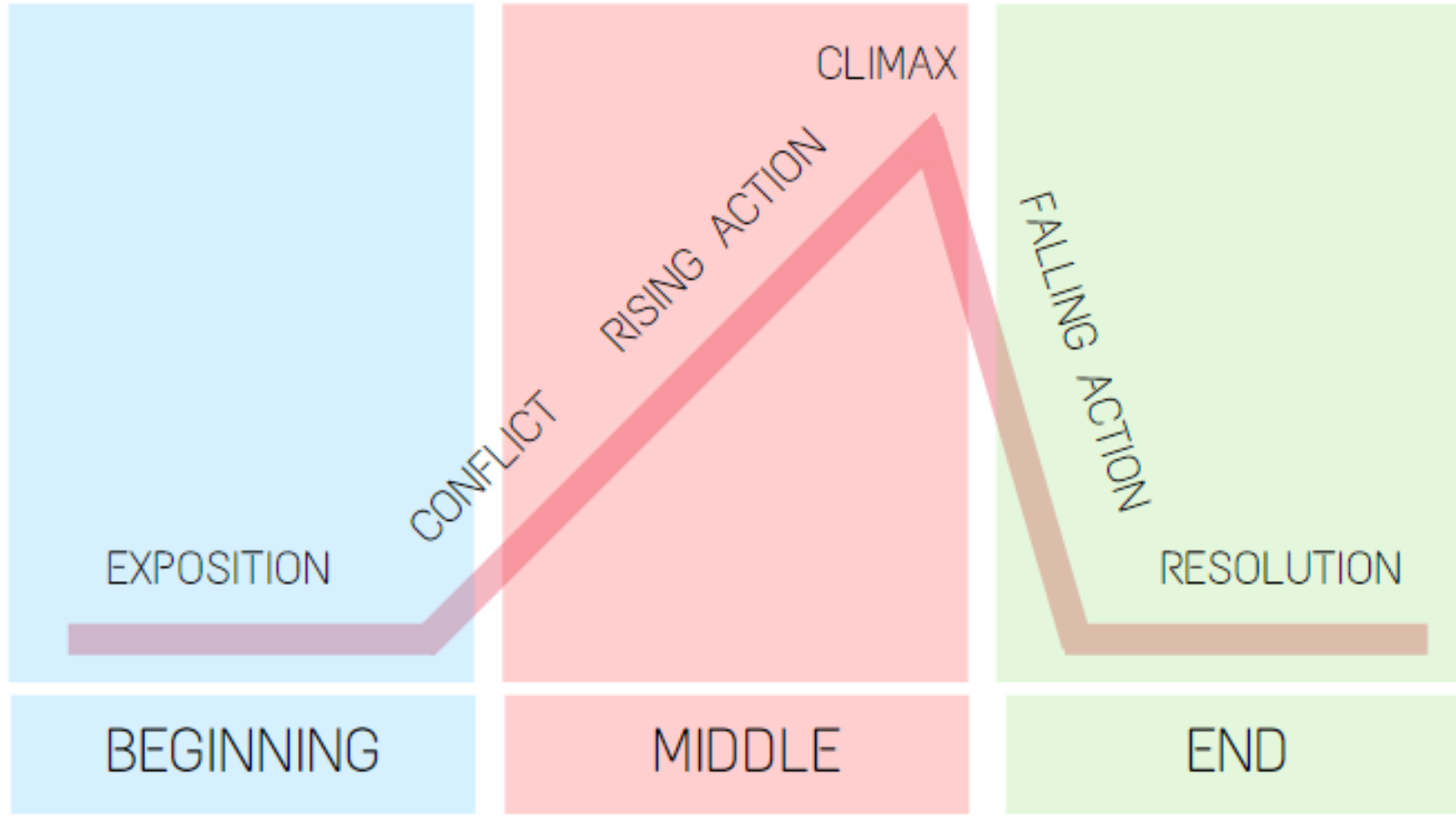
A woman in a light-colored suit stands in the center of a meeting room, smiling and pointing towards the camera. She is holding a tablet. Several people are seated around a table in front of her, with their hands raised in the air, suggesting an interactive or celebratory meeting. The scene is brightly lit with a white background.

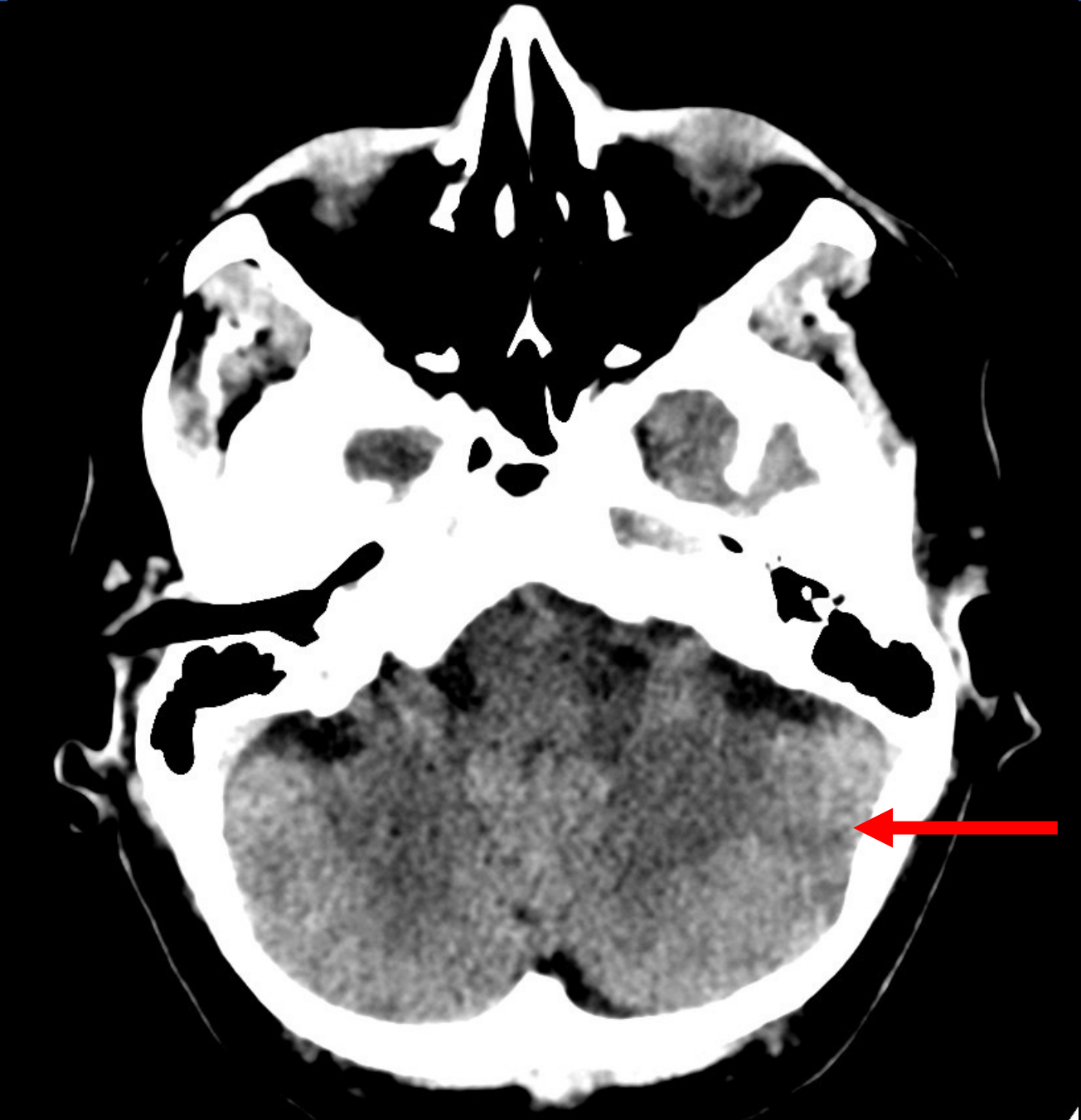Interaction

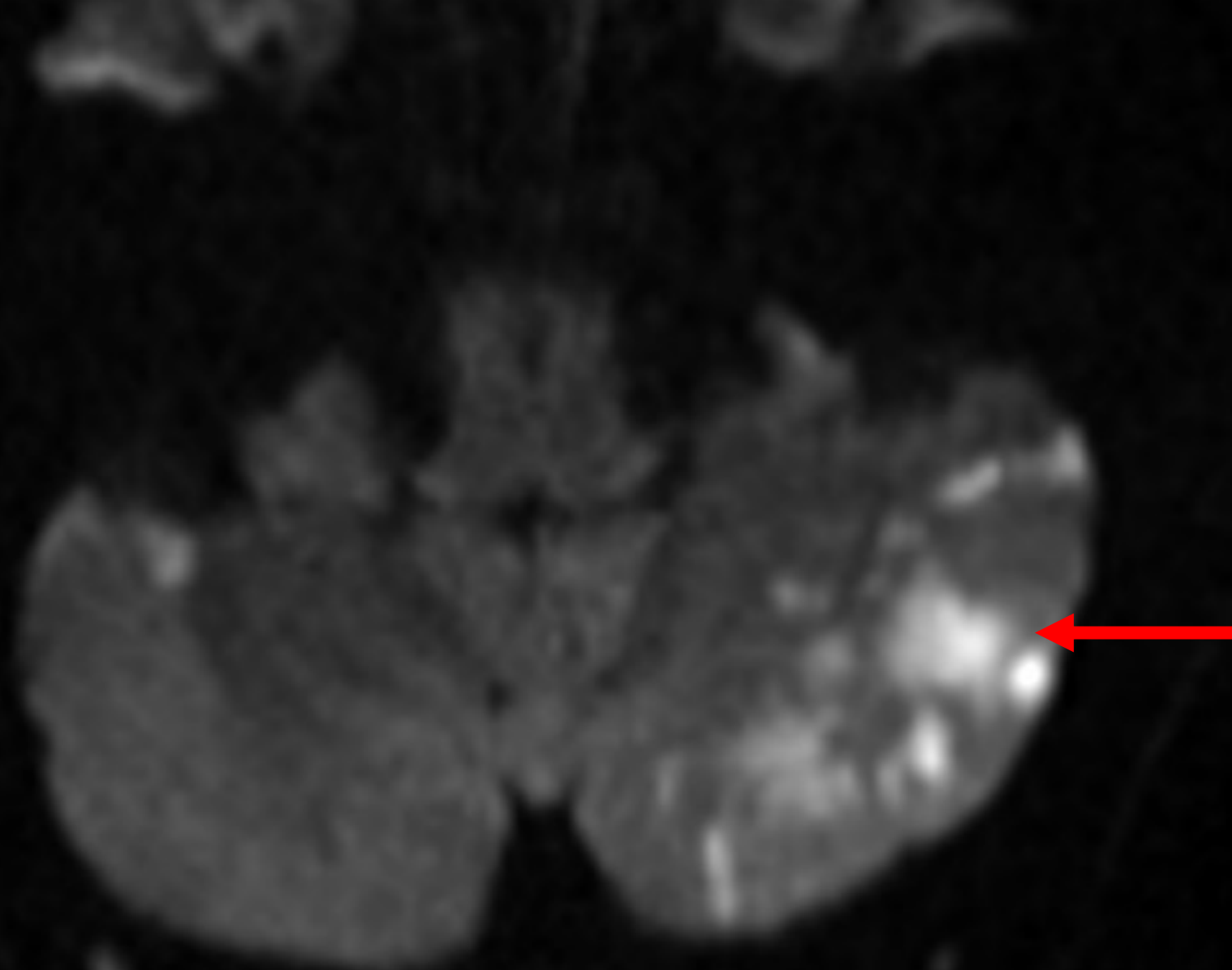


Preparation

Structure







An illustration on a dark teal background. A hand in a dark blue suit sleeve holds a red megaphone. The megaphone is angled towards the right, with several grey, jagged sound waves emanating from its horn. The text 'Reinforce the presented information / messages' is written in white, sans-serif font across the center of the image, partially overlapping the megaphone and the sound waves.

Reinforce the presented
information / messages

Examples:

To sum up



Multiple



Menacing



Frequent



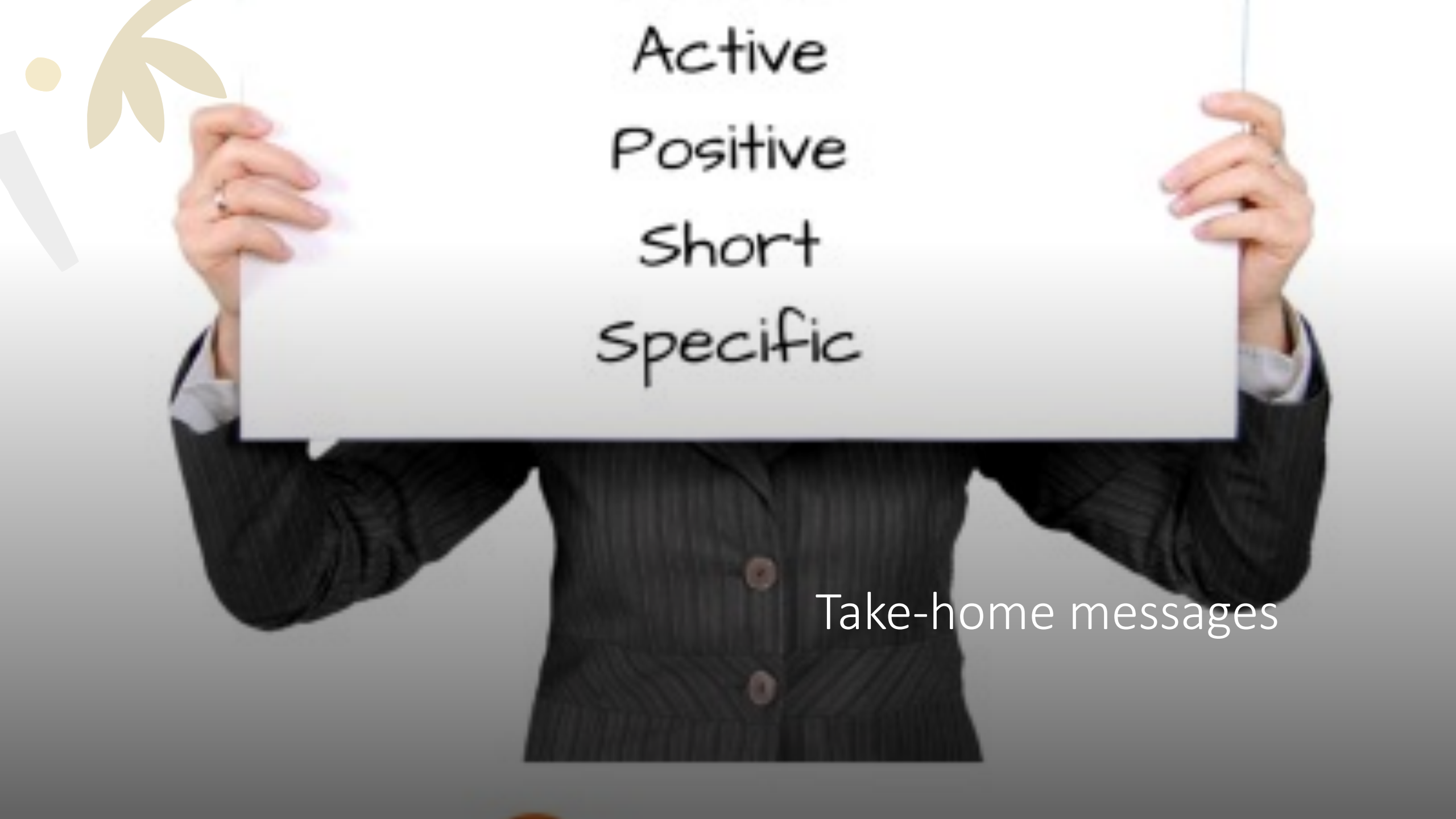
Mimicry



Responsive to acute treatment



But may have a specific treatment

A person wearing a dark pinstriped suit jacket is holding a large white rectangular sign in front of their chest. The sign contains the text 'Active', 'Positive', 'Short', and 'Specific' stacked vertically. The person's hands are visible at the top corners of the sign. In the top left corner of the image, there is a stylized graphic of a person with a yellow circle for a head and a grey shape for a body, with a yellow leaf-like shape above it. The background is a plain, light grey gradient.

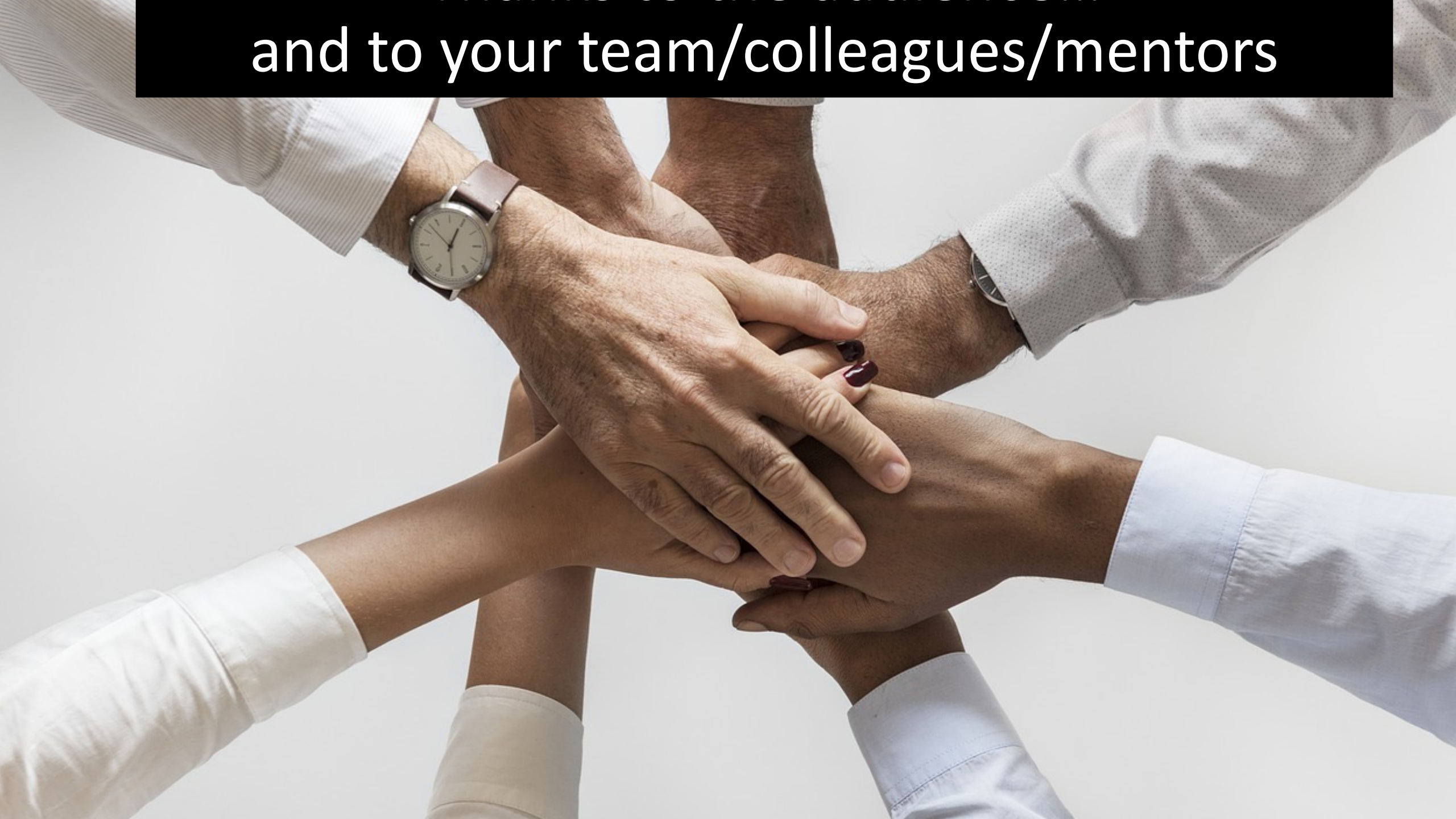Active
Positive
Short
Specific

Take-home messages

Putting the evidence in context



and to your team/colleagues/mentors





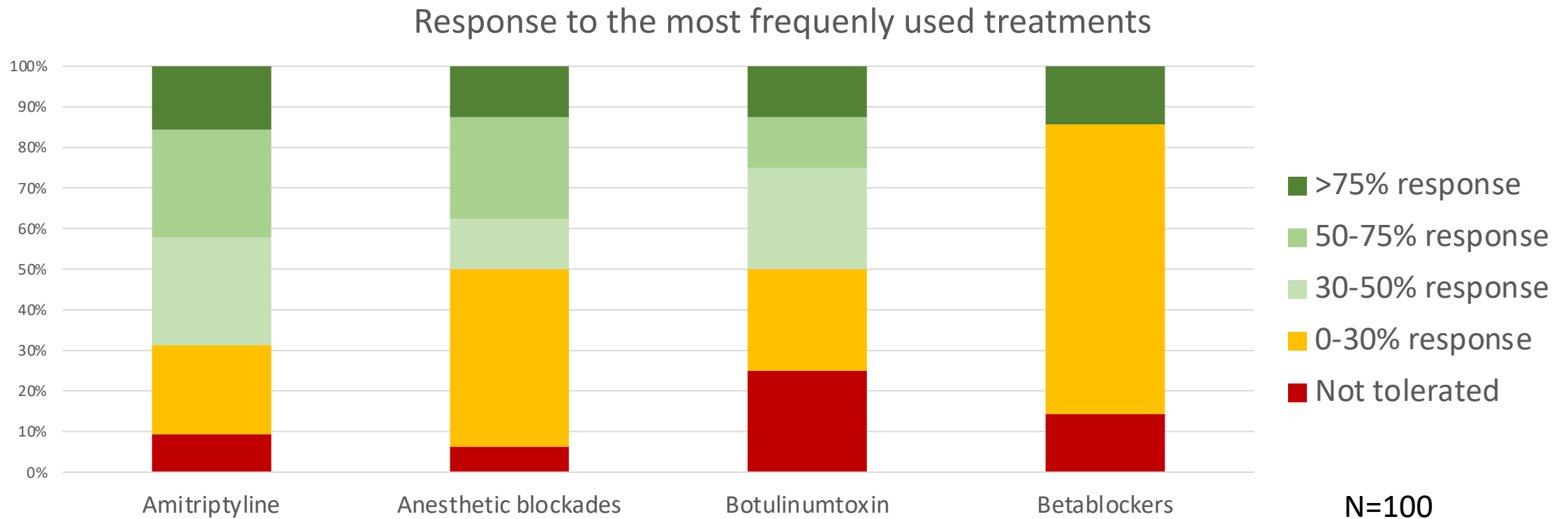
Answering questions

~~• Good question...~~

• I don't know



Anticipate possible questions



Thank you for your time

- David García Azorín
- davilink@hotmail.com

